


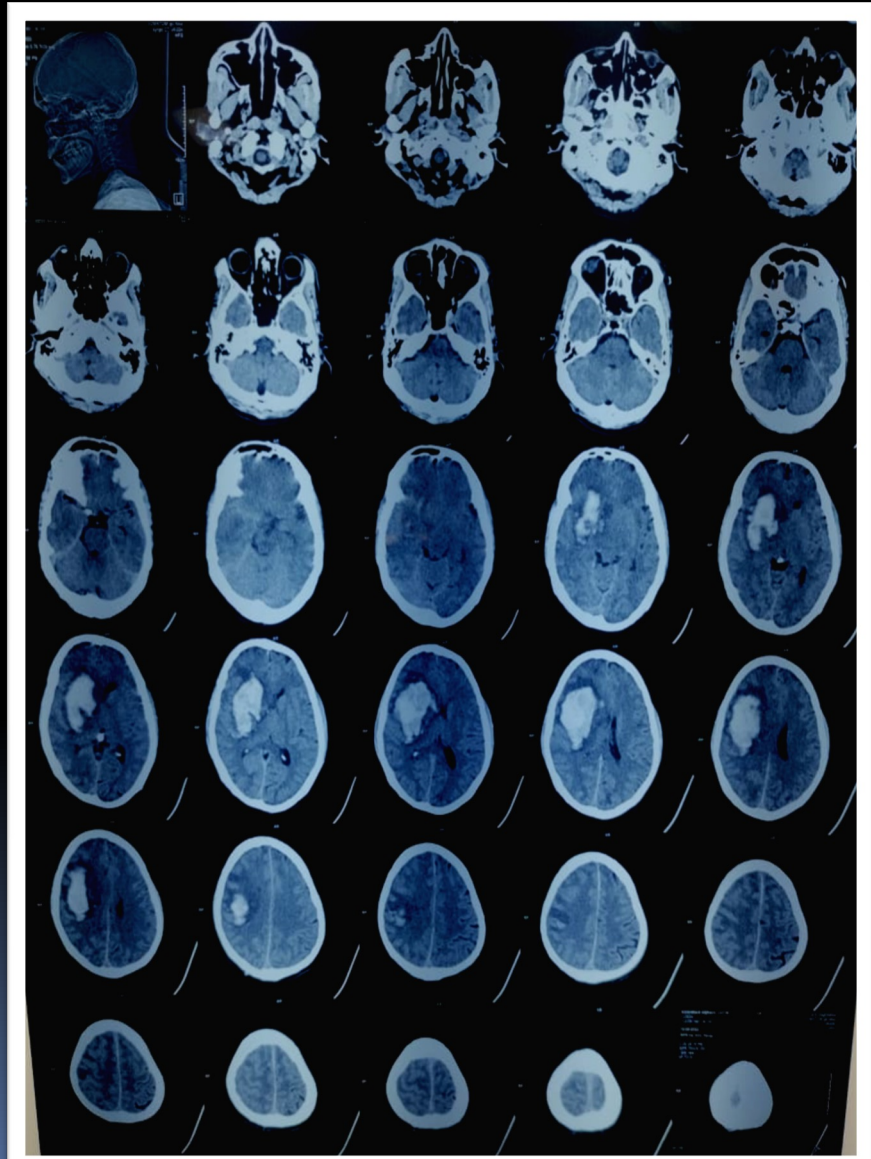
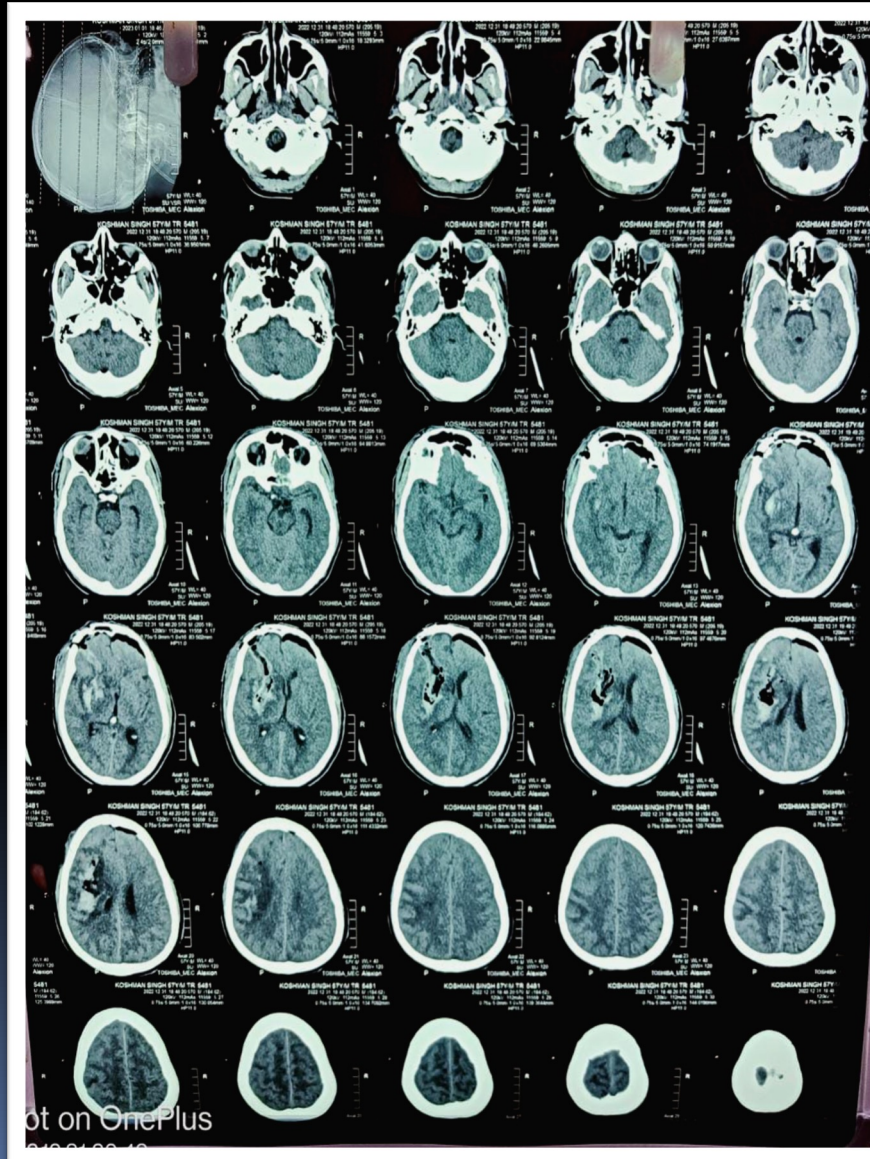


ENDOSCOPIC OPERATION OF A LARGE BASAL GANGLIA BLEED

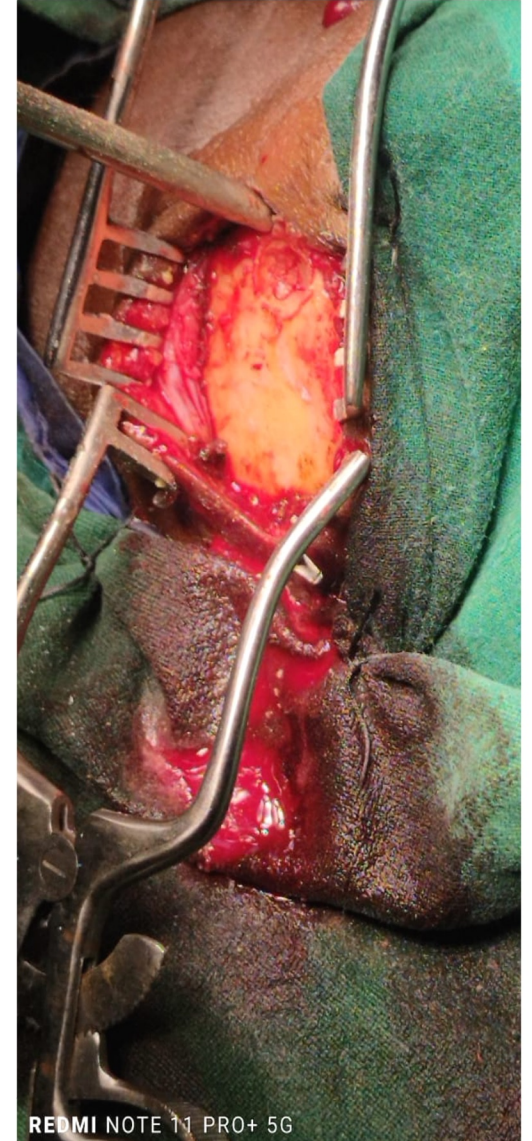
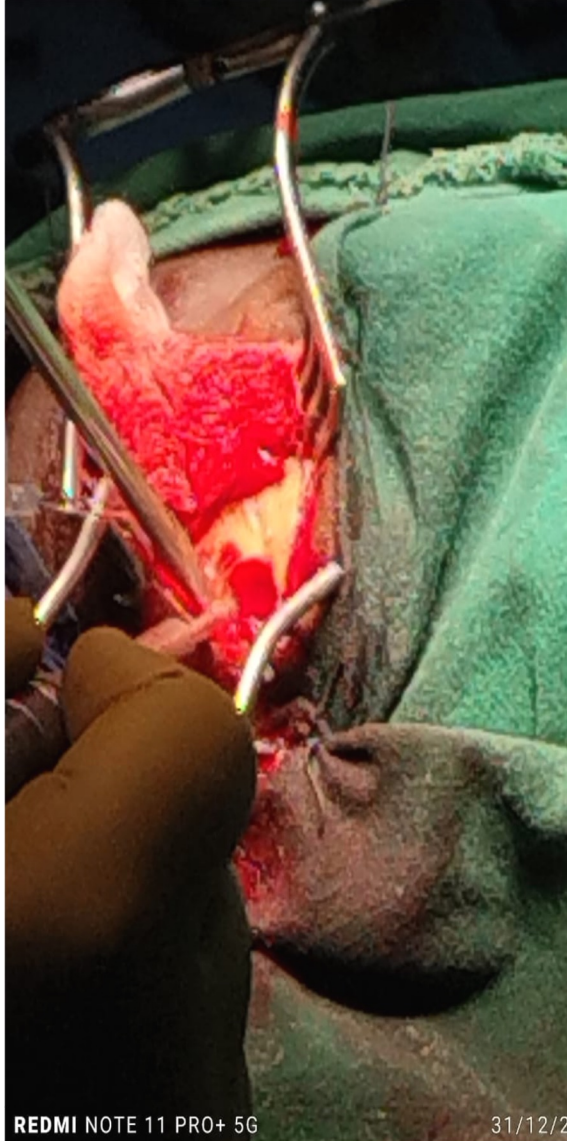
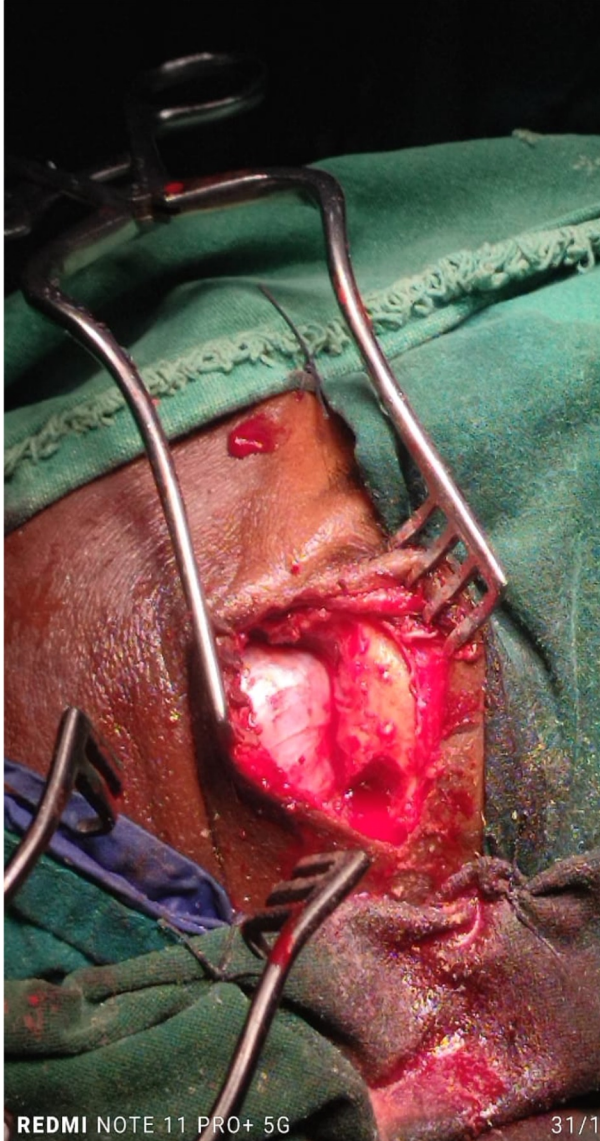
Department of Neurosurgery

- 
- A 71 year male presented with large basal ganglia bleed detected by CT scan
 - An endoscopic operation through supraorbital key hole approach was performed by the Neurosurgery team.
 - Surgery was uneventful and the result was good.

CT Scan



Operative images



Operative Video

