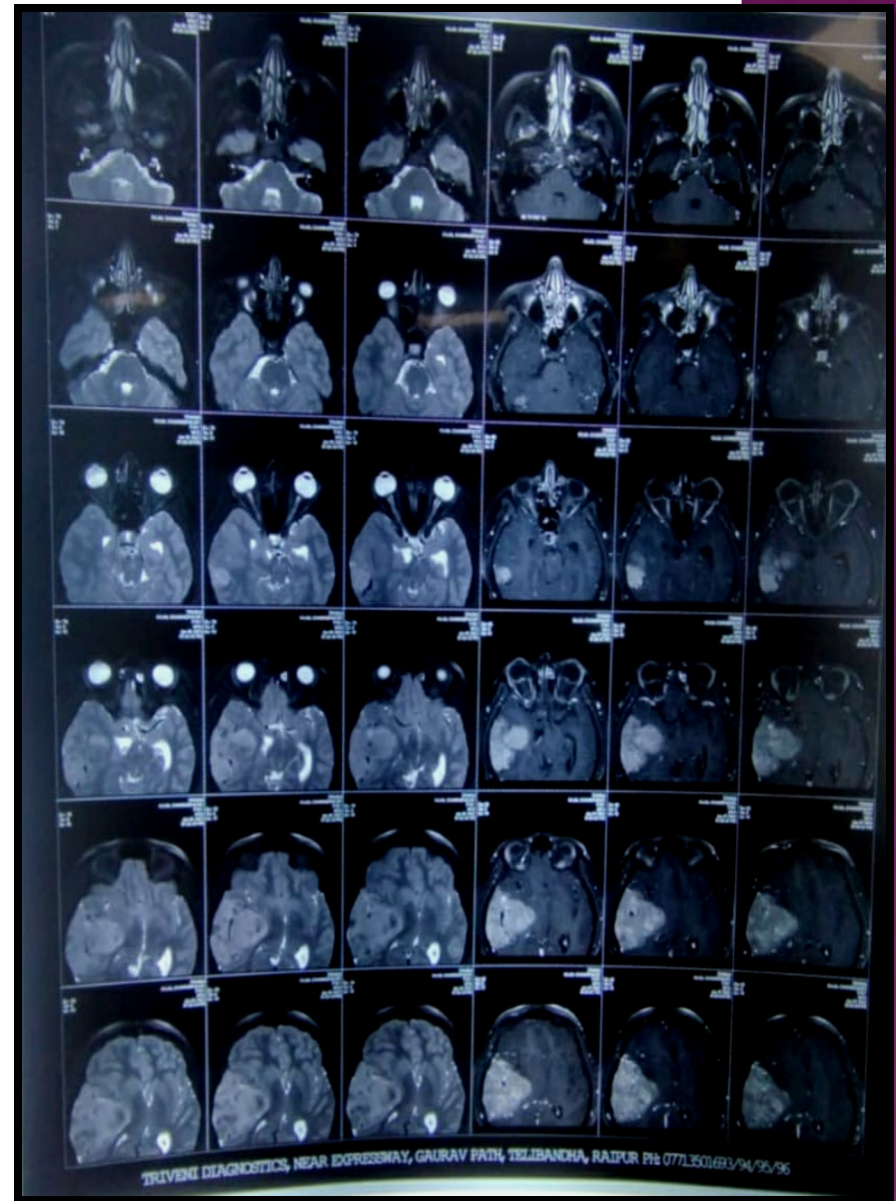
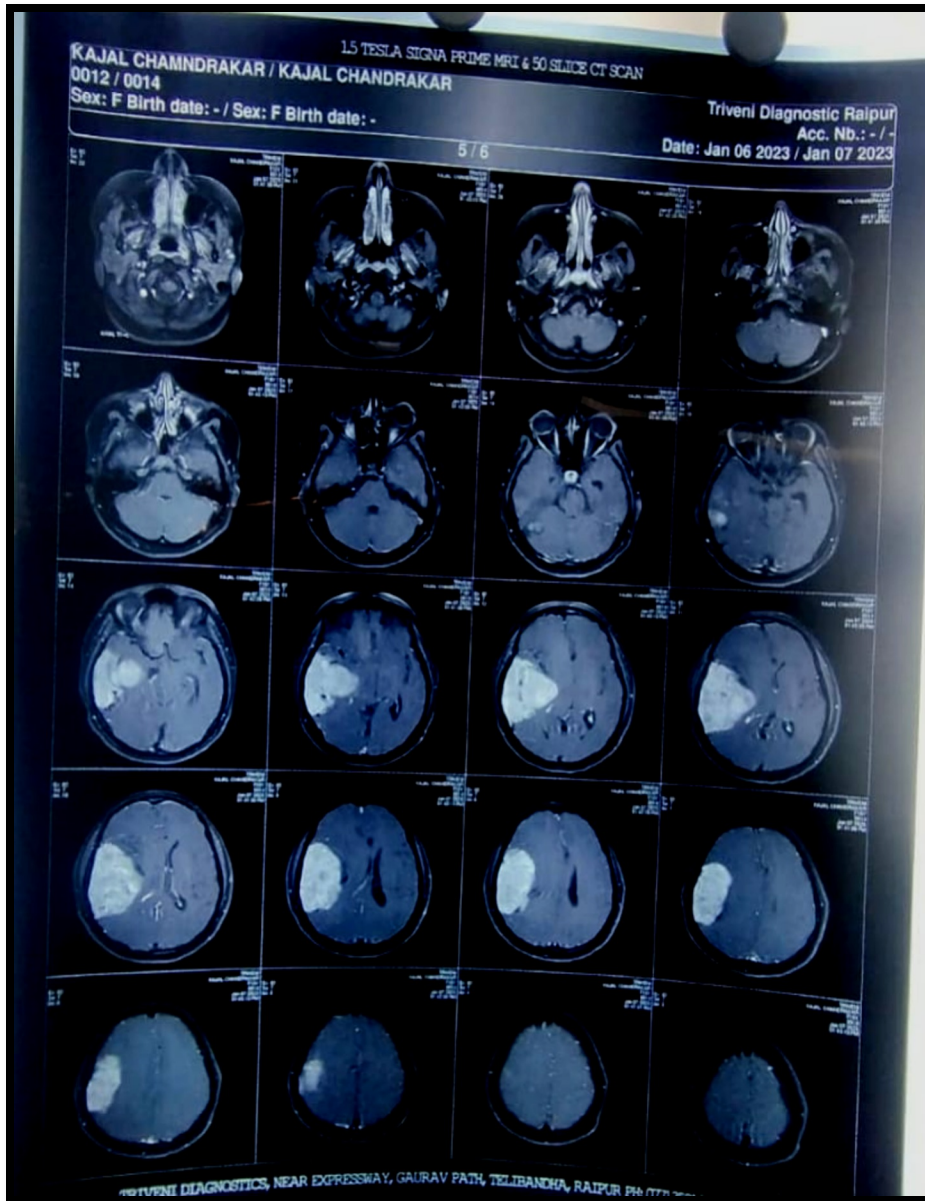


MICRO NEUROSURGICAL OPERATION OF A LARGE MENINGIOMA

Department of Neurosurgery

- ⊙ A 16 year old girl presented with headache and visual loss.
- ⊙ MR imaging was suggestive of large meningioma.
- ⊙ A micro neurosurgical operation was performed by the Neurosurgery team.

MRI



Operative video



Post operative recovery

