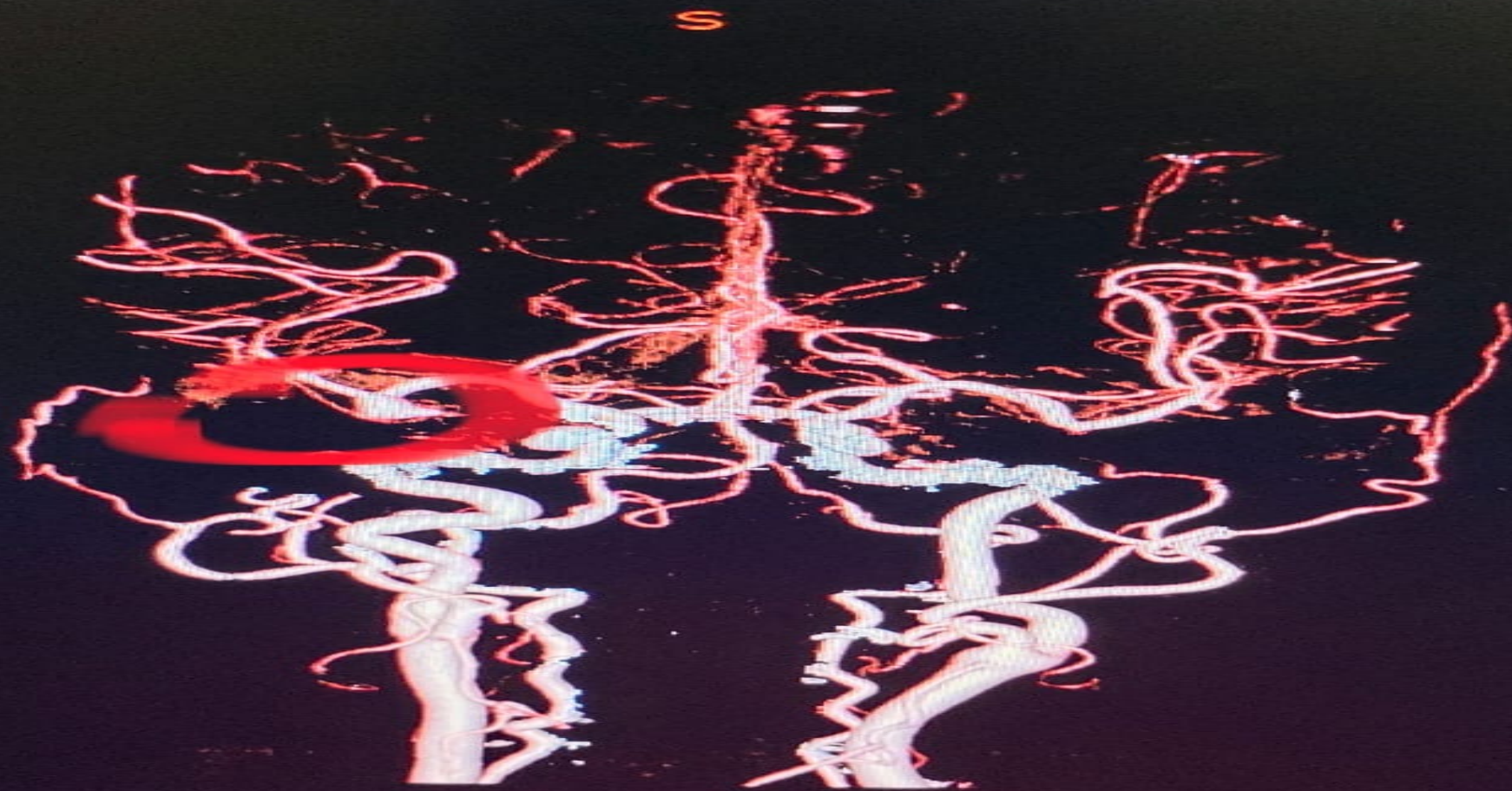


- 52 yr. old hypertensive female with subarachnoid haemorrhage with sever headache.
- CT ANGIOGRAPHY revealed large meddle cerebral artery aneurysm
- Clipping done at SSIMS NEUROSURGERY TEAM



S



Shot on vivo Z1Pro
Vivo AI camera



