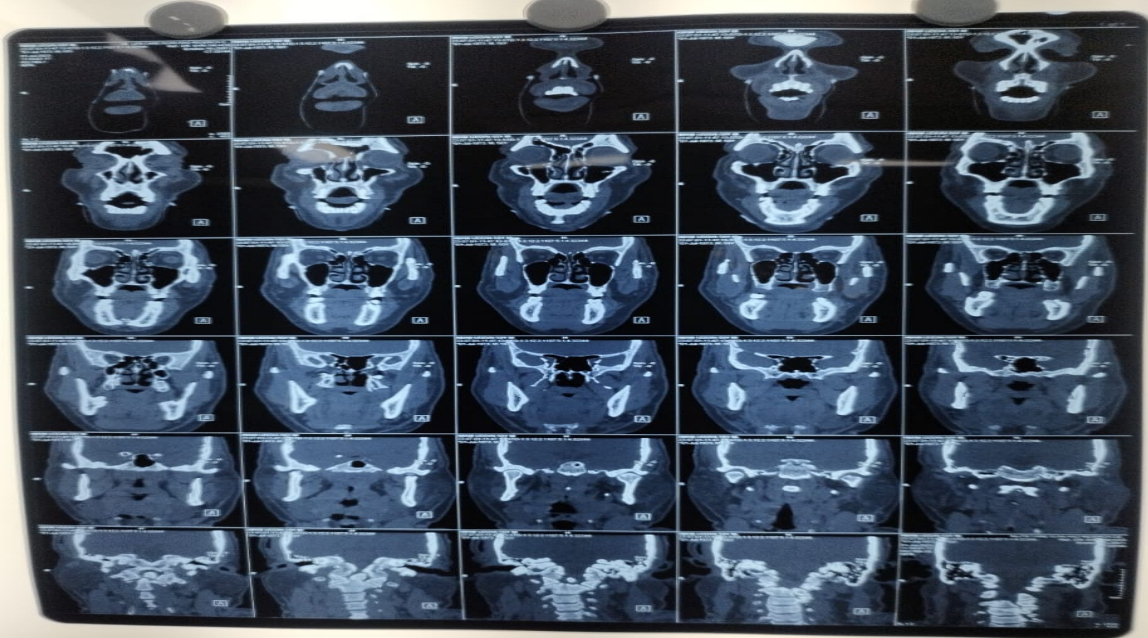
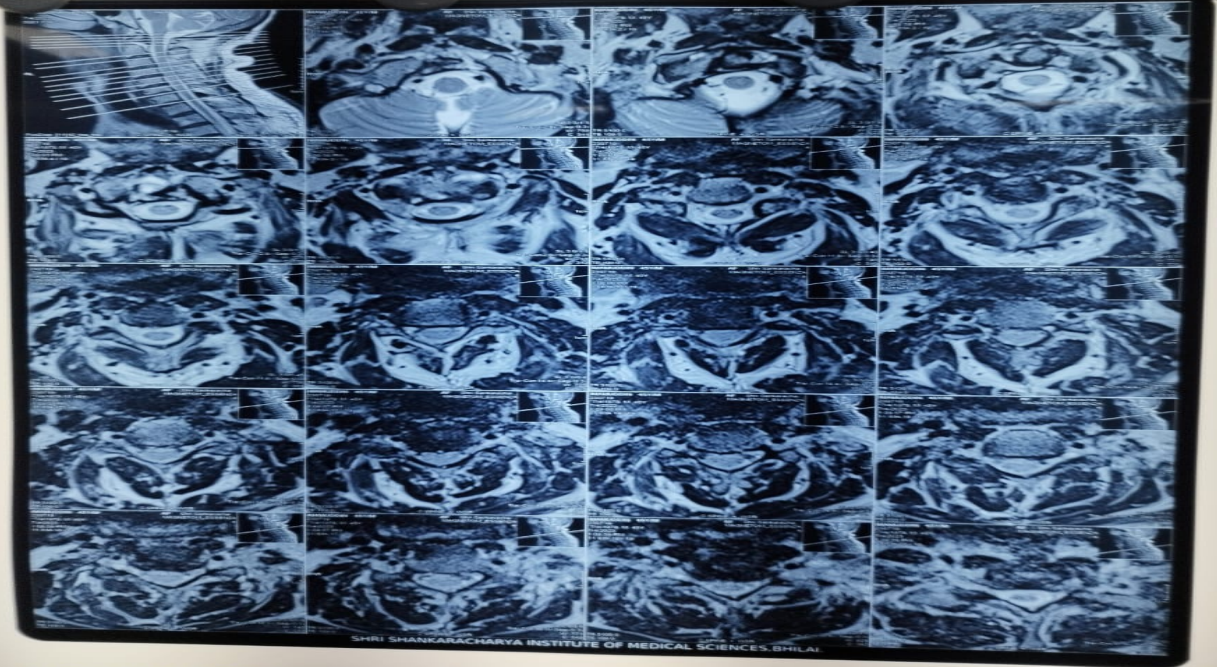


- Patient is victim of train accident fall from running train develop neck pain and weakness all limbs MRI suggested fracture of C2 type 2 hangmans fracture managed by single lag screw.
- Very rare surgery



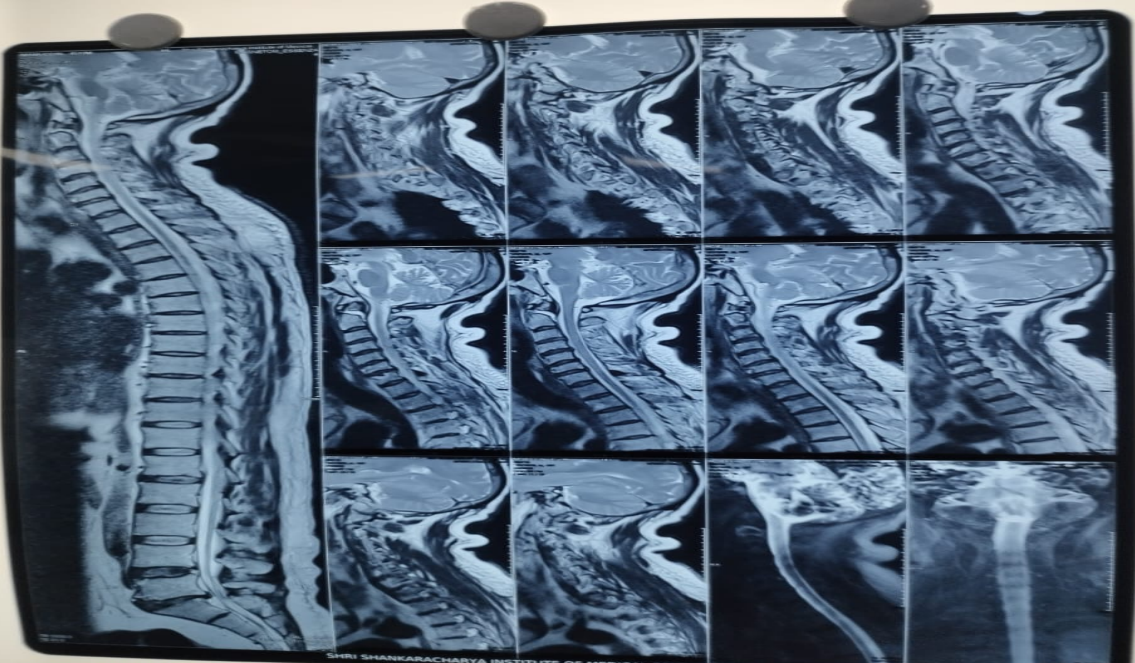
REDMI NOTE 11 PRO+ 5G

12/07/2023 11:45



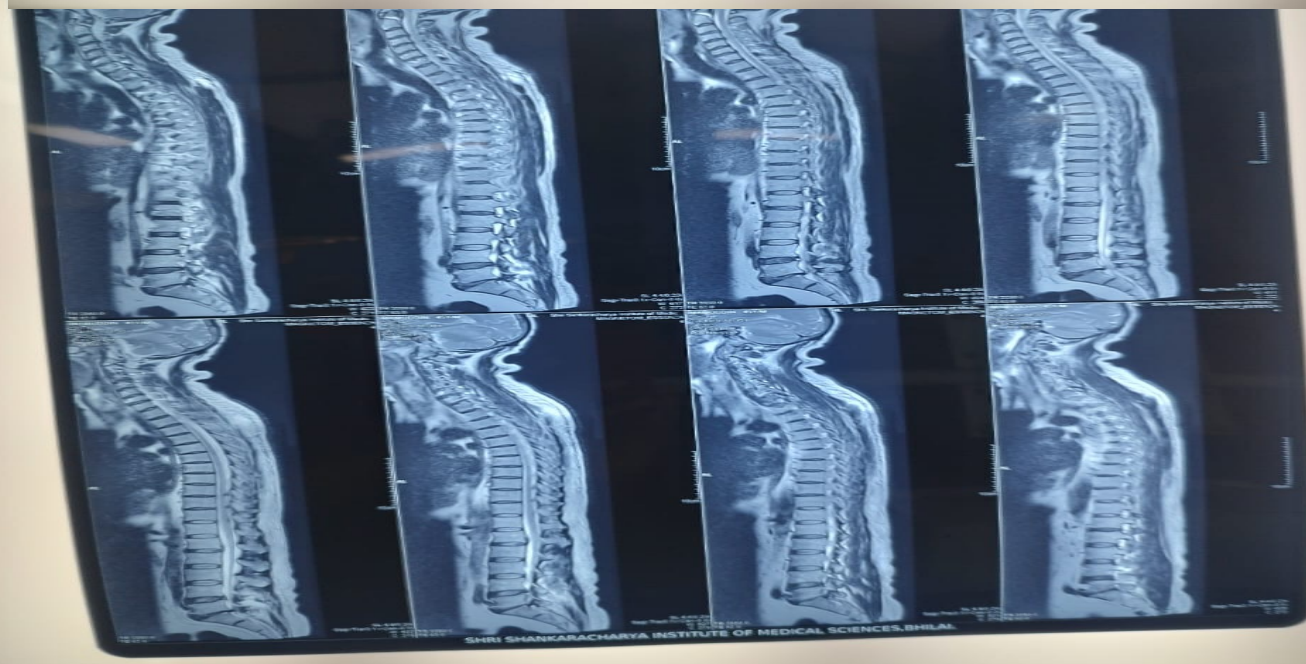REDMI NOTE 11 PRO+ 5G

12/07/2023 11:45



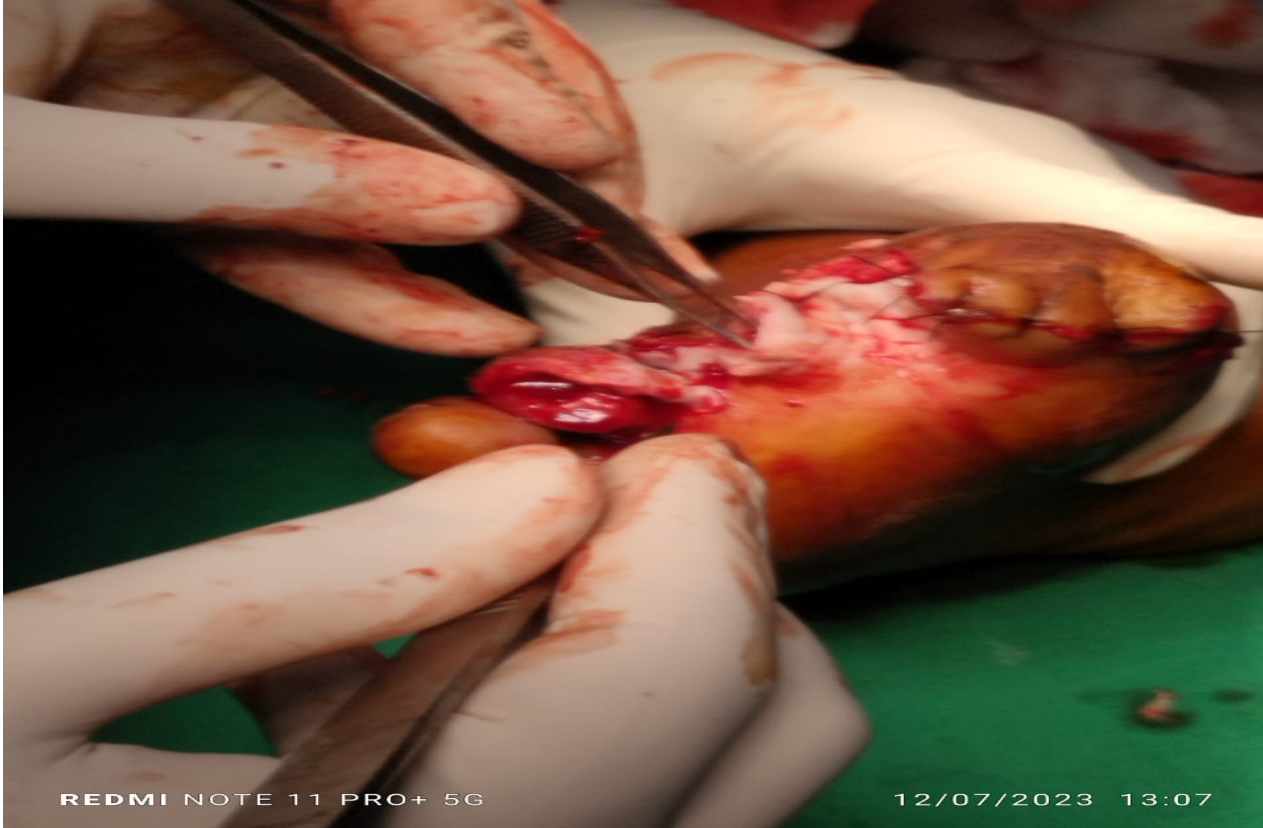
REDMI NOTE 11 PRO+ 5G

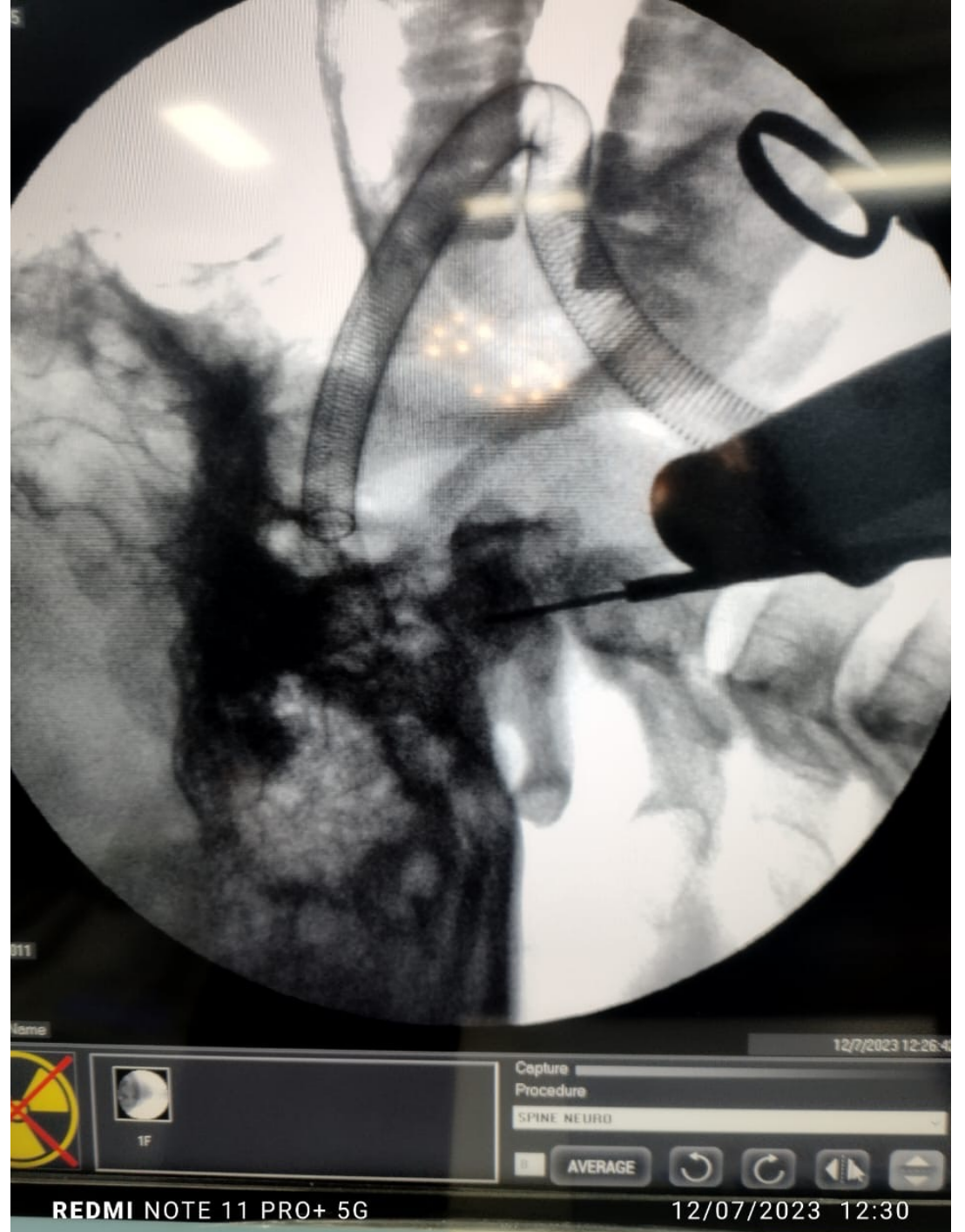
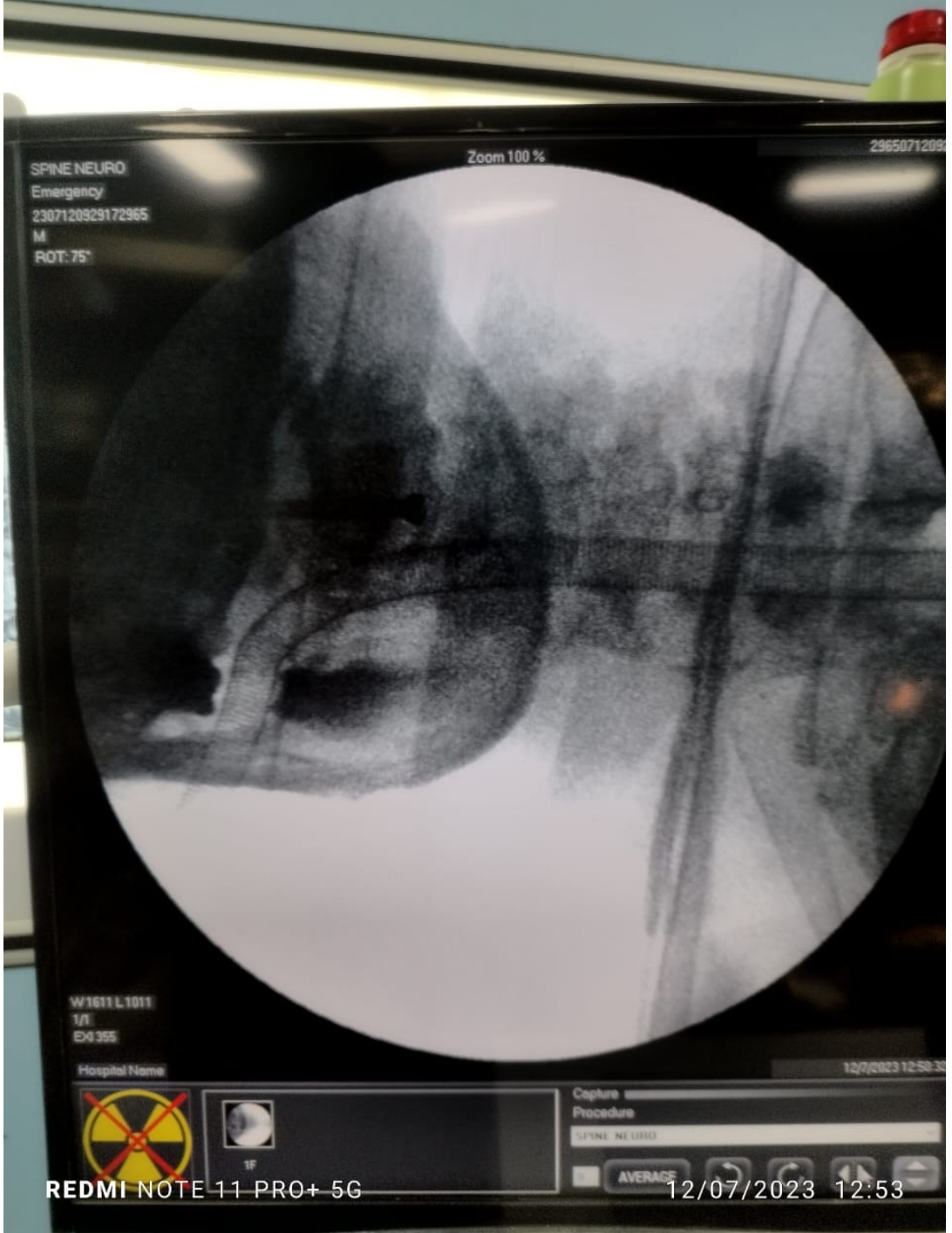
12/07/2023 11:46



REDMI NOTE 11 PRO+ 5G

12/07/2023 11:46







Video showing complete recovery